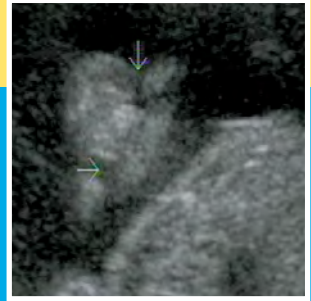
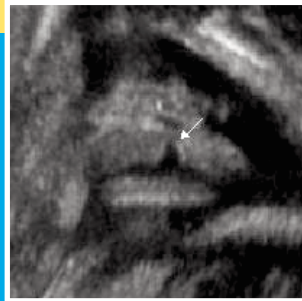
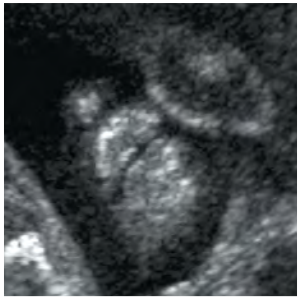# CLEFT LIP & PALATE

## A GUIDE FOR SONOGRAPHERS

Prepared by **CLAPA** in association with



*The Fetal Medicine Unit, St George's Hospital, London*

**Please complete details of your REGIONAL CLEFT CENTRE to where all referrals should be made**

**Centre name:**

**Team Coordinator contact name:**

**Phone number:**

If you are unsure where your Cleft Centre is located please contact CLAPA (see back page).

## CLEFT LIP AND PALATE a guide for sonographers

*prepared by:*

**CLAPA**

*in association with:*

**The Fetal Medicine Unit, St George's Hospital, London**

*Authors:*

**Trish Chudleigh and Katy Cook**

**Fetal Medicine Unit**

**St George's Hospital**

**London**

*November 2001*

# CLEFT LIP & PALATE

---

A GUIDE FOR SONOGRAPHERS

## CONTENTS

4	Embryological development of the lip and palate
6	Incidence of cleft lip and palate
6-8	Examining the fetal face with ultrasound
9	Limitations of ultrasound
10-12	Describing clefts correctly
13	Report writing and its implications
14	Talking to the parents
15	What else to look for
16-17	After the diagnosis
18	Terminology
19	References

---

# Cleft lip and/or palate why does it happen?

## Embryological development of the lip and palate

It is important to appreciate that the upper lip and palate form separately and over different gestational age ranges.

Although clefts in the lip and palate often occur together they arise from different embryological processes.

*The upper lip* develops from the growing together and fusing of the tissue that forms the nose and the centre of the face. The following tissue masses are involved: the two lateral nasal prominences, the two lateral maxillary prominences and the maxillary nasal prominence. Formation of the upper lip takes place between the 7th and 9th week of gestation (post LMP).

*The palate* develops from the growing together and fusing of the tissue that forms the centre of the upper lip and gum and the sides of the inner mouth. The following tissue masses are involved: the two lateral palatine processes, the nasal maxillary prominence and the nasal septum. Formation of the palate takes place between the 7th and the 14th week of gestation (post LMP).

The embryological processes involved in the formation of the upper lip and palate are described in detail below.

The future nose forms from two *nasal prominences* that develop on each side of the embryonic head. These grow towards each other and fuse with a central tissue mass called the *median maxillary nasal prominence*. The median maxillary nasal prominence gives rise to the *prolabium* or central

portion of the upper lip including the *philtrum*, the *premaxilla* or central portion of the alveolar ridge and the anterior portion of the hard palate or *median palatine process*. This is also known as the **primary palate**. The nasal prominence gives rise to the outer portion of the upper lip, the outer portion of the alveolar ridge, the premolars and the molars. The premaxilla gives rise to the central portion of the alveolar ridge and the four incisor teeth. It should be noted that there is a site of fusion on each side of the median nasal prominence, and these are called the labial grooves. Clefting of the lip will occur along one or both labial grooves. It is thought to be due to poor vascularity affecting the epithelial cells at these sites.

The palate forms from the fusion of the primary palate and the **secondary palate**. The secondary palate forms from two *palatine processes* that develop from the sides of the embryonic "mouth" and grow towards the midline. These processes fuse with each other centrally to form the secondary palate. The secondary palate fuses with the primary palate anteriorly and the nasal septum superiorly to form the *hard palate*, *soft palate (or velum)* and *uvula*. The hard palate lies anteriorly to the soft palate and uvula. As with the upper lip there is a site of fusion on each side of the primary hard palate called the *anterior palatine* or *incisive sutures*. There is an additional line of fusion, between the two palatine processes. Clefting of the palate will occur along the anterior palatine sutures and/or along the line of fusion between the two palatine processes.

## Incidence of cleft lip and palate

- The overall incidence of cleft lip and palate malformations in live births in the United Kingdom and in most parts of Europe is approximately 1:700.<sup>1</sup>
- Of the three conditions, isolated cleft palate (CP) is the most common (40%). Cleft lip and palate (CLP) of varying degrees make up to 35% of the total number of clefts (25% unilateral and 10% bilateral) and isolated cleft lip (CL) constitutes 25%.<sup>2</sup>

## Examining the fetal face for cleft lip and/or palate with ultrasound

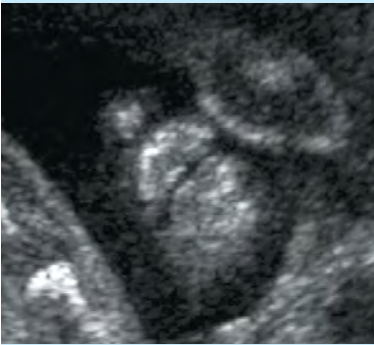Examination of the fetal face is a component part of current guidelines for second trimester ultrasound examination.<sup>3,4</sup> The fetal face should be examined in three planes, coronal, sagittal and transverse, to ensure that maximum information is obtained. The lips are best imaged in the coronal plane, the fetal profile in the sagittal plane and the alveolar ridge in the transverse plane. Multiple views in each plane, rather than a single section, should be used to evaluate the relevant structures.

### Imaging the lips and nose

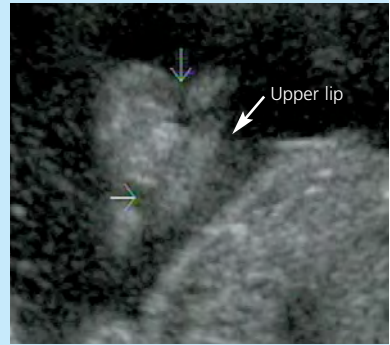
The upper lip and nose are best identified from a coronal view (Figs 1a and 1b). Clefting can involve the lip only (*incomplete cleft lip*) or may also involve the ipsilateral nostril (*complete cleft lip*). The prominent premaxilla that frequently is present with a bilateral complete cleft of the upper lip is best identified

from a sagittal view of the fetal face (Fig 2). This is also the optimal plane for identifying micrognathia.

### Coronal plane views

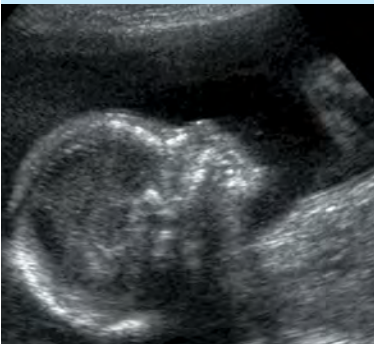

*Fig 1a. Normal lips and nose*

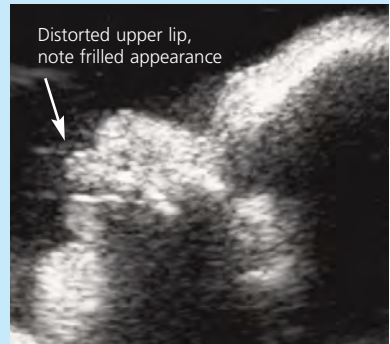


*Fig 1b. Bilateral cleft lip and nose (arrow heads)*

### Sagittal plane views



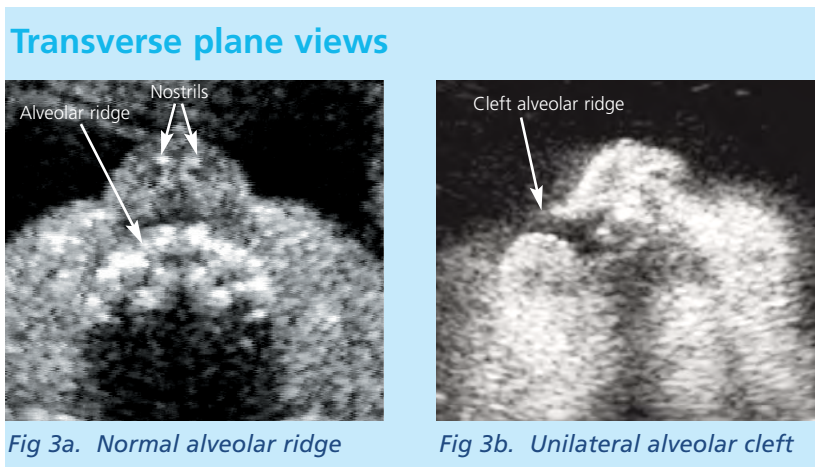
*Fig 2a. Normal fetal profile*



*Fig 2b. Abnormal fetal profile due to unilateral cleft*

## Imaging the alveolar ridge

In cases of cleft lip it is important to determine whether the alveolar ridge is normal or also cleft. The normal and cleft alveolar ridge are best demonstrated in the transverse plane (Figs 3a and 3b).



## Imaging the palate

Isolated clefts of the palate are rarely identified by ultrasound. However, a small jaw may suggest the possibility of Pierre Robin sequence, where a cleft palate is associated with a small jaw (micrognathia) and a posteriorly-positioned tongue (glossoptosis).



## Limitations of ultrasound

Although the correct ultrasound examination technique should enable clefting of the upper lip to be identified it is unlikely that an isolated cleft of the palate will be seen prenatally. **WHAT IS OFTEN DESCRIBED AS A “CLEFT PALATE” ON ULTRASOUND IS USUALLY A CLEFT ALVEOLUS.**

In the event of finding a fetal facial cleft, we should **NOT** be using the blanket terminology of ‘cleft lip and palate’. This is because:

1. A more precise description of the defect is possible and should therefore be used
2. The palate may not be involved
3. The subsequent management and outcome differ depending on the degree of clefting involved

## Describing clefts correctly

### Types of cleft

When discussing clefts to parents three broad categories of cleft are used

#### 1. Cleft lip

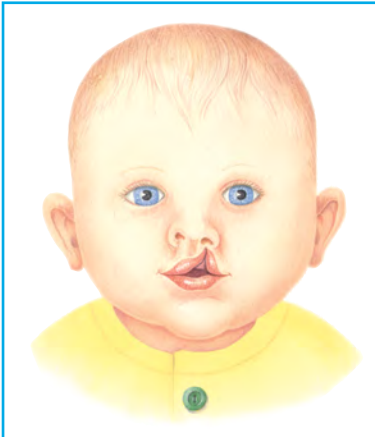This involves either:

- a) the lip only (Fig 4)
- b) the lip and nose
- c) the lip, alveolar ridge and nose

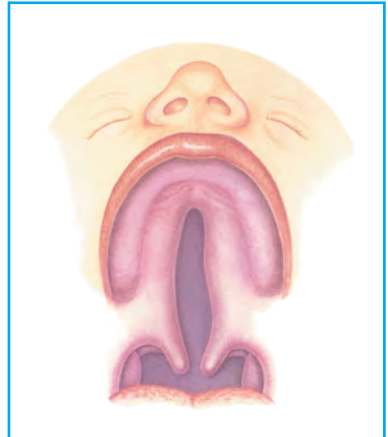
#### 2. Cleft palate

This involves either:

- a) the hard and soft palate (Fig 5)
- b) the soft palate only



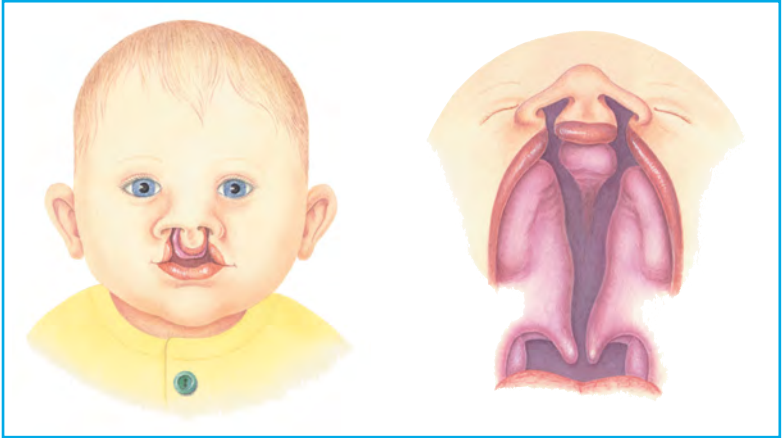
*Fig 4. Incomplete unilateral cleft lip*



*Fig 5. Cleft of hard & soft palate*

**3. Cleft lip and palate**

This involves the lip, alveolar ridge and hard and soft palate (Fig 6)

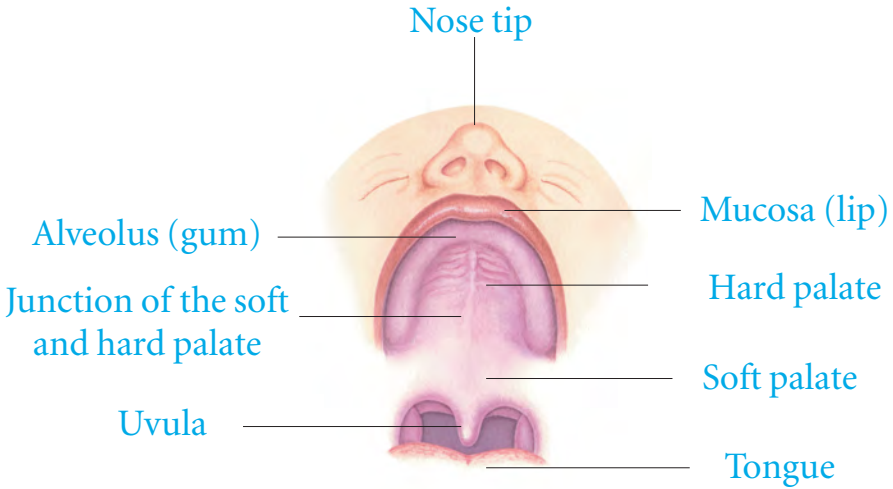


*Fig 6. Bilateral cleft lip, alveolus & palate*

Clefts of the lip may be unilateral or bilateral and all of the varieties of clefts described above may be incomplete in varying degrees.

When reporting the ultrasound findings to the clinical team to whom the parents will be referred you should describe your findings relative to four specific areas (Fig 7):

1. Lip and nose
2. Alveolar ridge or alveolus
3. Hard and soft palate (rarely detectable as an isolated finding)
4. Soft palate only (rarely detectable as an isolated finding)



*Fig 7 Normal anatomy of upper lip and palate*

The ultrasound views required to image the types of clefts described are given below.

Type of cleft	Structures involved	Ultrasound description	U/S views required for diagnosis
<b>Unilateral cleft lip</b>	a) upper lip	Unilateral cleft lip (incomplete)	Coronal & transverse
	b) upper lip & nose	Unilateral cleft lip (complete)	
	c) upper lip, nose & alveolus	Unilateral cleft lip (complete) & alveolus	
<b>Bilateral cleft lip</b>	a) upper lip	Bilateral cleft lip (incomplete)	Coronal, transverse & sagittal
	b) upper lip & nose	Bilateral cleft lip (complete)	
	c) upper lip, nose & palate	Bilateral cleft lip (complete) & alveolus	
<b>Cleft lip &amp; palate (unilateral/bilateral)</b>	Upper lip, nose, alveolus & palate	Cleft (unilateral/bilateral) lip, alveolus & palate	Coronal, transverse & sagittal
<i>Cleft palate (NB-rarely detectable)</i>	a) <i>hard palate</i> b) <i>soft palate</i> c) <i>hard &amp; soft palate</i>	<i>Cleft palate</i>	<i>Transverse</i>

## Report writing and its implications

- Use the correct terminology
- **DO NOT** mistake the alveolar ridge (alveolus) for the hard palate. If you are in any doubt, i.e. sub-optimal views have been obtained, seek a second opinion.
- Remember that there is a large difference in patient care, treatment and counselling between cases which do and do not involve the palate.
- **DO NOT** use the blanket term “cleft lip and palate”.
- With an isolated cleft lip, the infant will have no feeding/ swallowing difficulties or speech problems because of the cleft. Mum can breast feed if she wishes.
- If the alveolus is involved but the palate is intact, feeding / swallowing and speech should be normal. The approach taken by the Cleft Lip and Palate team in such cases is dependent on whether or not the palate is involved.

## Talking to the parents

When a facial cleft is suspected your role is to explain these findings and their implications to the parents in a way that they will understand. Complicated clinical terminology should be avoided. If, during a scan you suddenly state that “the baby has got a cleft lip” this is likely to leave the parents in a state of shock and may cause them stress that could be avoided. You need to find a way of explaining the findings in a manner that is honest, informative and sympathetic.

If you suspect a cleft but are not certain either of its extent and/or whether it is an isolated finding, it may be helpful to gather your thoughts and /or speak to a colleague about your suspicions before talking to the parents. In which case, the following phrase might be helpful:

*“I can’t get all the right views with the baby lying in this position. Can I ask you to have a seat outside for 10 minutes and then we’ll have another look.”*

### What NOT to say in the event of finding a facial cleft

1. “The baby’s lying in a difficult position and I can’t see the baby’s face properly. I’ll arrange for you come back for another scan in a week’s time”
2. “This machine isn’t good enough for all the views I need. I’ll arrange for you come back for another scan in a week’s time when we can have a look on a better machine”
3. “Your baby looks as if it’s got a cleft lip. I’d like the doctor to take a look so I’ll arrange for you to come back for another scan in a few days time.”

## Suggested phrasing in the event of finding an isolated facial cleft

*"I've had a thorough look at the baby's anatomy. Everything looks normal except I think there is a cleft in the baby's upper lip and possibly in the gum as well. What I'd like to do is to speak to your consultant and he can explain in more detail what this means for the baby. He may also want to refer you to the Fetal Medicine Unit."*

## What else to look for and what else to consider

When a facial cleft is suspected, care must be taken to view the fetal face in the three standard views. A careful survey of the fetus should also be performed in order to determine the presence of any other anomalies - the parents should be referred on to your local Fetal Medicine Unit for a more conclusive ultrasound examination if necessary. When associated anomalies are present, possible aneuploidy (particularly Trisomies 13 and 18) or a genetic syndrome should be considered. Pierre Robin sequence is the most common association with cleft palate. Velocardial facial syndrome is also fairly common but almost always occurs with isolated cleft palate and other palatal and pharyngeal abnormalities, and is rarely detected by prenatal ultrasound. Parents should be informed that they have access to genetic counselling.

The parents may also wish to access various electronic, paper and video-based sources for further information. Currently available sources are listed in the next section.

## After the diagnosis

After diagnosis it is important that arrangements are made for referral to your local Cleft Lip and Palate Team **at the earliest opportunity**. It is essential that telephone contact should be made with the Team **before** the parents leave the scanning department so arrangements can be made by the team to meet the family, either at home or at an outpatients appointment. The team will be able to discuss with the parents the various issues that surround having a baby with a cleft. These issues include:

- Planning the immediate post delivery care
- Feeding, breast and bottle feeding assessment - specialist feeding bottles will be provided by the Cleft Team treating the baby
- The type of surgery needed and when it will be performed
- The implications of the cleft for the child's speech development
- The implications of the cleft for the child's dentition
- The emotional impact of a baby with a cleft on the whole family

Parents' ability to receive information is varied and affected by many factors. It is important that the pace at which such information is given is appropriate for the family.

Specific details regarding timing of operations and other treatment should be given by the cleft team members at the centre which will be caring for the baby.



**CLAPA** together with The Royal College of Surgeons provide a range of leaflets suitable for new and prospective parents. Your department should keep copies of these leaflets, together with any other relevant written information provided by your department, to give to the parents. Relevant literature includes:

- Antenatal Diagnosis of Cleft Lip and Palate (CLAPA)
- Help with Feeding (CLAPA)
- Children Born with Cleft Lip and Palate (CLAPA)
- The treatment of Cleft Lip and Palate. A Parents' Guide (The Royal College of Surgeons)<sup>5</sup>
- Children born with Cleft Lip and Palate - The school years (CLAPA)

The following contact details of CLAPA should be available for parents:

CLAPA	Green Man Tower, 332B Goswell Road, London EC1V 7LQ
Tel:	020 7833 4883
Email:	info@clapa.com
Website	www.clapa.com

## Terminology

The following structures are involved in the normal development of the upper lip and palate (see Figs 7 and 8).

**Alveolar ridge/alveolus** - the dental arch of the maxilla

**Alar base** - tissue supporting the area surrounding the nostril

**Columella** - the area directly between the two nostrils

**Cupid's bow** - the central portion of the upper lip below the philtrum

**Hard palate** - the anterior, bony part of the palate

**Mucosa** - the upper and lower lips

**Philtrum** - the central part of the face lying between the upper lip and the nostrils. It is delineated on either side by the philtral ridge

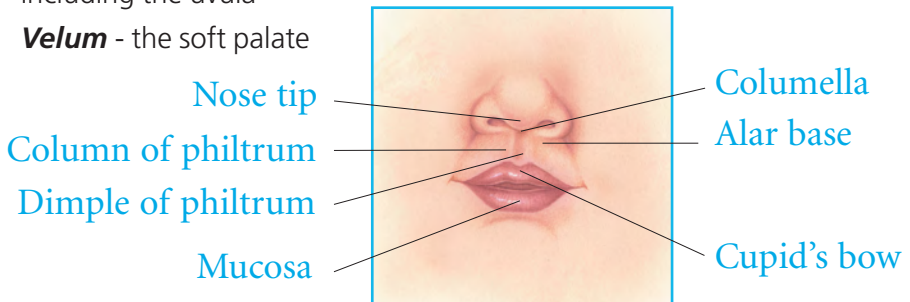
**Premaxilla** - the central part of the alveolar ridge and the primary palate

**Primary palate** - a posterior extension of the alveolar ridge lying between the anterior edges of the hard palate

**Prolabium** - the central portion of the face including the columella, philtrum and vermillion

**Soft palate** - the mobile, posterior, fibromuscular part of the palate including the uvula

**Velum** - the soft palate



*Fig 8 Normal anatomy of the nose and lips*

## References:

1. Clinical Standards Advisory Group. *Cleft Lip and/or Palate. Report of a CSAG Committee 1998. London: The Stationery Office.*
2. Sommerald, B. (1994) The management of cleft lip and palate. *Current Paediatrics*. Vol 4, pp 189-195.
3. United Kingdom Association of Sonographers (2001) *Guidelines for Professional Working Standards - Ultrasound Practice.*
4. Royal College of Obstetricians and Gynaecologists (2000). *Routine Ultrasound Screening in Pregnancy. Protocol, Standards and Training.* London: RCOG Press.
5. The Royal College of Surgeons of England (2000). *The Treatment of Cleft Lip and Palate. A Parents' Guide.* Cheshunt: Jameson Press.

### **Recommended reading:**

Malek, R. (2001) *Cleft Lip and Palate. Lesions, Pathophysiology and Primary Treatment.* Martin Dunitz Ltd

Watson, ACH; Sell, D A & Grunwell, P. (Eds.) (2001)  
*The Management of Cleft Lip and Palate.*  
Whurr Publishers, London.



***CLAPA Head Office:***  
**Green Man Tower, 332B Goswell Road,**  
**London EC1V 7LQ**

***Tel: 020 7833 4883***

***Fax: 020 7833 5999***

***Email: [info@clapa.com](mailto:info@clapa.com)***

***Web site: [www.clapa.com](http://www.clapa.com)***

***Contact Head Office for details of local CLAPA Contacts***

**Booklet produced with support from Department of Health**

*Design & layout by Stephen Read*  
*020 8516 1906, e-mail: [sefread@hotmail.com](mailto:sefread@hotmail.com)*